



## NEWS



SUMMER 2025

### Rutland House Veterinary Hospital

#### Abbotsfield Road

St. Helens WA9 4HU  
Tel: 01744 853520

#### Haydock Veterinary Surgery

142 Church Road, Haydock,  
St. Helens, Merseyside WA11 0LA  
Tel: 01942 716640

#### The Village Veterinary Surgery

3 Bryn Road, Bryn,  
Wigan WN4 0AA  
Tel: 01942 721562

#### Albany Veterinary Surgery

26 Whiston Lane, Huyton,  
Merseyside L36 1TY  
Tel: 0151 489 4106

#### Windsor Veterinary Surgery

177 Grange Lane, Gateacre,  
Liverpool L25 5JY  
Tel: 0151 428 5688

#### Freckleton Veterinary Clinic and Aquazone

89-91 Freckleton Road,  
St. Helens WA10 3AS  
Tel: 01744 453429

#### Culcheth Veterinary Surgery

487 Warrington Road, Culcheth,  
Warrington WA3 5QU  
Tel: 01925 764088

#### Maple Veterinary Surgery

95 Maple Crescent,  
Penketh, Warrington  
Tel: 01925 726378

#### Grappenhall Veterinary Surgery

181 Knutsford road,  
Grappenhall, Warrington  
Tel: 01925 600000



## Worming worries!

Unlike infectious diseases that we can vaccinate against, your pets are in all likelihood continually coming into contact with worms. So what are the major types of worms affecting our pets? There are three important groups to be aware of...


**Roundworms** are most commonly found in young animals but can infect adults as well. Many puppies and kittens are born infected with roundworms because they cross the placenta and are also in the milk. Roundworms look like long strings of spaghetti but are usually only seen if there is a heavy burden or you give your pet a dewormer. Adult roundworms shed eggs which are passed out in your pets faeces and infect the environment. The eggs become infective within a few weeks and pets can become re-infected by unwittingly eating the eggs, often whilst grooming. Additionally the eggs can pose a risk to humans if accidentally ingested.

**Tapeworms** live in the intestines and shed small *mobile* segments that pass out in the faeces and are often found around the tail areas of cats. As the segments break down, they release eggs into the environment. These eggs may be eaten by *intermediate hosts* – these include **fleas** and **small rodents** such as mice and voles. As a result, tapeworms can be acquired via food (cats eating small rodents) or via swallowing an infected flea during grooming. Pets with tapeworms may not show any obvious clinical signs, meaning that they can be carried silently. Some animals will show failure to thrive, malaise and diarrhoea.

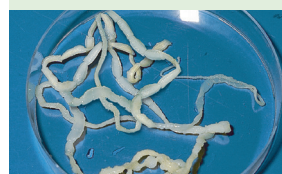**Lungworm:** As well as being a menace to your garden, slugs and snails can carry lungworm (*Angiostrongylus vasorum*). Dogs are infected by eating slugs or snails carrying lungworm larvae, or even just eating grass that has slug or snail slime on it. Lungworm are swallowed as tiny larvae which migrate to the right side of the heart, where they develop into adult worms. Here they produce eggs which hatch out into larvae, which migrate to the lungs causing coughing. The larvae are then coughed up, swallowed and passed out in the faeces. Symptoms can range from none, to a soft cough, to life threatening bleeding disorders.

Regular prescription worming and flea treatments for your pet, picking up dog faeces, good hand hygiene, plus attempting to prevent your dogs eating slugs and snails, will all help to keep you and your pet safe. How often you should protect your pet depends on their lifestyle and habits – so come and have a chat and we can hopefully make sure they have a worm-free life!

#### Rogues gallery of worms.....




**Roundworms** are long, white and spaghetti like.



**Tapeworms** are long segmented worms which shed segments.



larvae, or even just eating grass that has slug or snail slime on it. Lungworm are swallowed as tiny larvae which migrate to the right side of the heart, where they develop into adult worms. Here they produce eggs which hatch out into larvae, which migrate to the lungs causing coughing. The larvae are then coughed up, swallowed and passed out in the faeces. Symptoms can range from none, to a soft cough, to life threatening bleeding disorders.



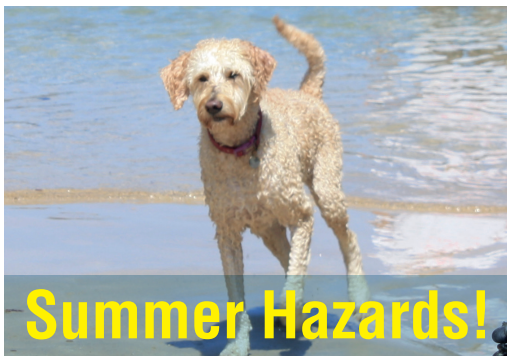## Dental disease - is my rabbit affected?

Did you know that rabbits are unusual in that they have open rooted teeth? This allows their teeth to *continuously* grow at a rate of 1-3mm per week, enabling wild rabbits to grind and chew large quantities of tough and very fibrous grass and plants.

Problems are often encountered in pet rabbits fed a diet of mainly pelleted food, with insufficient roughage. The edges of their teeth do not wear down properly and they can develop sharp points which eventually cause ulcers on the inside of the mouth and tongue, which can result in inappetence, dribbling and weight loss. Their daily diet needs to be *very* fibrous – so mainly hay, dark leafy vegetables and about an egg cup full of commercial rabbit nuggets. Please get in touch if you would like us to check your rabbit's teeth.



Misaligned and overgrown incisor (front) teeth



## Summer Hazards!

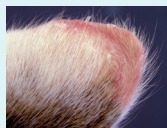Finally, the summer is here! Most of us, and our pets, love the warmer weather but it brings with it its own particular set of challenges and potential problems. Here are a few tips to keep your pet fit and well at this time of year:

**Heat Stroke** is an extremely serious problem and can be fatal. Although all dogs are at risk, the shorter faced breeds, like Staffies, Pugs and Bulldogs are most vulnerable, and the danger is even greater if they are over-weight. To prevent problems, avoid exercising your pets in the midday heat and make sure they don't over-exert themselves at any time. If you become worried, move them to a cool, shaded place, give them lots to drink and call us immediately.



Guinea pigs and rabbits can also struggle in the heat. Naturally, they would use burrows to keep cool in hotter weather but this isn't always an option. Consider moving their enclosures to a shady cooler location and ensure the water is regularly changed and with multiple sources in the event one gets tipped over.

**Sunburn:** Cats are natural sun-bathers and for many cats this causes no problems. However cats with white ear tips and noses are prone to sunburn and this can lead to cancerous changes over time. High factor sun block applied to the at-risk areas helps to minimise this risk. Call us if you are worried.



Ear tip of a cat with early (reddened) cancerous changes. If your pet is showing signs of skin changes, please call us at once



**Grass seeds:** the grass awns of the meadow grasses can easily penetrate into different places, especially feet and ears. These can be very painful and can appear as sudden head shaking if one enters an ear or a sore area on a foot. It is always a good idea to groom your pets regularly, and especially after walks, to keep a close eye out for grass seeds.

**Flies** are another hazard. Flies are very attracted to rabbits if they have soiled bottoms – here they lay their eggs which rapidly hatch out into flesh eating maggots. Try and keep rabbit bottoms clean, check them at least twice a day for maggots and call us at once if you are concerned.

Finally, please remember that the temperature in cars can rise rapidly and death from heat stroke can follow in minutes, so **pets should NEVER be left unattended in cars.**

## Keep a lookout for lumps and bumps!

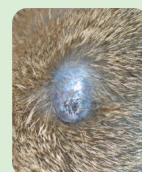


Lumps and bumps come in a variety of shapes and sizes and can be detected early on by regular grooming (also excellent for looking for fleas, ticks and other parasites!). If you notice a skin lump, it's important to get in touch so we can assess it.

Lumps can have several underlying causes including: allergic reactions (such as insect bites), abscesses, hernias (often seen in younger pets) and tumours.

Tumours are understandably the most worrying and are either benign (tend to be slow growing and stay in one place), or malignant (which are often fast growing and can spread).

As with many conditions, speed is of the essence and a delay in starting the appropriate treatment can be the difference between a small treatable lump and a much larger one which is very much harder to deal with.



Skin lump on a cat (left). Ticks (right) are common in the UK and Ireland and may be mistaken as small lumps.

## Ear disease - is your pet affected?



Does your pet show signs of head shaking and ear scratching? These are commonly seen in dogs and cats and, combined with other symptoms such as ear redness and discharge – point to ear disease as a problem.

The ear is protected externally by a pinna (or flap). A narrow ear canal carries sound to the ear drum where it passes onto the middle and inner ear.

Unlike the situation in humans where middle ear disease is common, most of the problems seen in pets occur in the *external* ear canal – with an often painful condition called **otitis externa** (or canker).

The key to diagnosing and treating otitis externa is to identify the *underlying* cause. These include:

- **Ear mite infestations** with *Otodectes cynotis* is commonly seen in puppies and kittens and are typically associated with a crusty brown discharge (see photo right). The mites can be identified under the microscope (see inset photo).

- **Allergic dermatitis:** since the ear canal is lined with skin, it can be affected by *localised* allergic skin disease affecting the skin lining the external ear canal. This is often seen as part of a more generalised allergic skin condition, typically involving foot scratching and face rubbing, with certain breeds particularly prone to it.

- **Foreign bodies** such as grass awns (see panel left) are a common problem in pets and typically present with sudden onset severe head shaking.

In order to effectively treat otitis externa it is very important to identify the underlying cause (see above). Some, such as ear mites or foreign bodies are easily identified and treated. However, over time, the underlying cause is commonly obscured and made worse by *secondary* opportunistic bacterial and fungal infections.

So – if your pet is showing signs of ear disease, such as head shaking, ear rubbing or just having a smelly ear, it is very important that we examine them and establish the *underlying* cause of the problem as soon as we can, since this will give us the best chance of a successful long term outcome. Call us today for an appointment!

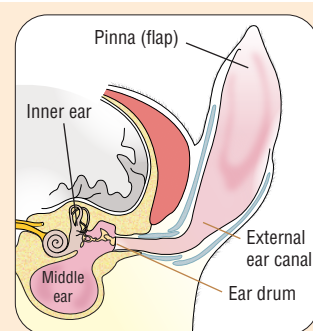
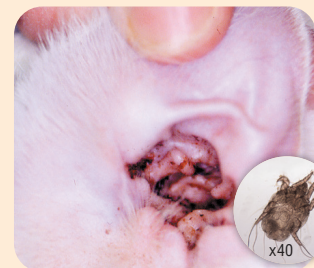
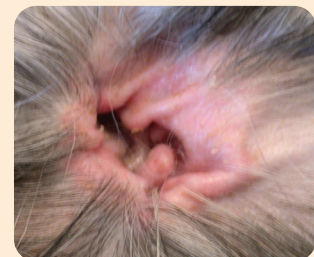

Diagram of the ear. Most problems occur in the vertical and horizontal ear canals



**Cat:** Opening to the ear canal in a cat with a crusty brown discharge typical of **ear mites** *Otodectes cynotis* (inset)



**Dog:** Opening to the ear canal in a dog showing redness and itchiness typical of **allergic skin disease**